

# Treatment of intractable pruritus in patients with cholestasis with molecular adsorbents recirculating system dialysis: a case series

Magdalena Antoszevska<sup>1</sup>, Piotr Sychalski<sup>2</sup>, Gerda Elisabeth Villadsen<sup>3</sup>, Niels Kristian Muff Aagaard<sup>3</sup>

<sup>1</sup>Department of Dermatology, Venereology, and Allergology, Medical University of Gdansk, Gdansk, Poland

<sup>2</sup>Department of General, Endocrine, and Transplant Surgery, Medical University of Gdansk, Gdansk, Poland

<sup>3</sup>Department of Hepatology and Gastroenterology, Aarhus University Hospital, Aarhus, Denmark

Gastroenterology Rev 2021; 16 (3): 254–256  
DOI: <https://doi.org/10.5114/pg.2021.108992>

**Address for correspondence:** Magdalena Antoszevska, Department of Dermatology, Venereology, and Allergology, Medical University of Gdansk, Gdansk, Poland, phone: +48 698 748 705, e-mail: [mmantoszevska@gmail.com](mailto:mmantoszevska@gmail.com)

Pruritus commonly occurs in patients with cholestatic liver diseases. Pruritus that is refractory to pharmacological treatment may be an indication for liver transplantation [1–3]. Pathogenesis of hepatic pruritus is still not fully understood. However, it is probably associated with the accumulation of pruritogens in plasma and other tissues as a result of cholestasis [4] (bile salts, bile acids, progesterone metabolites, lysophosphatidic acid, endogenous opioids [1]).

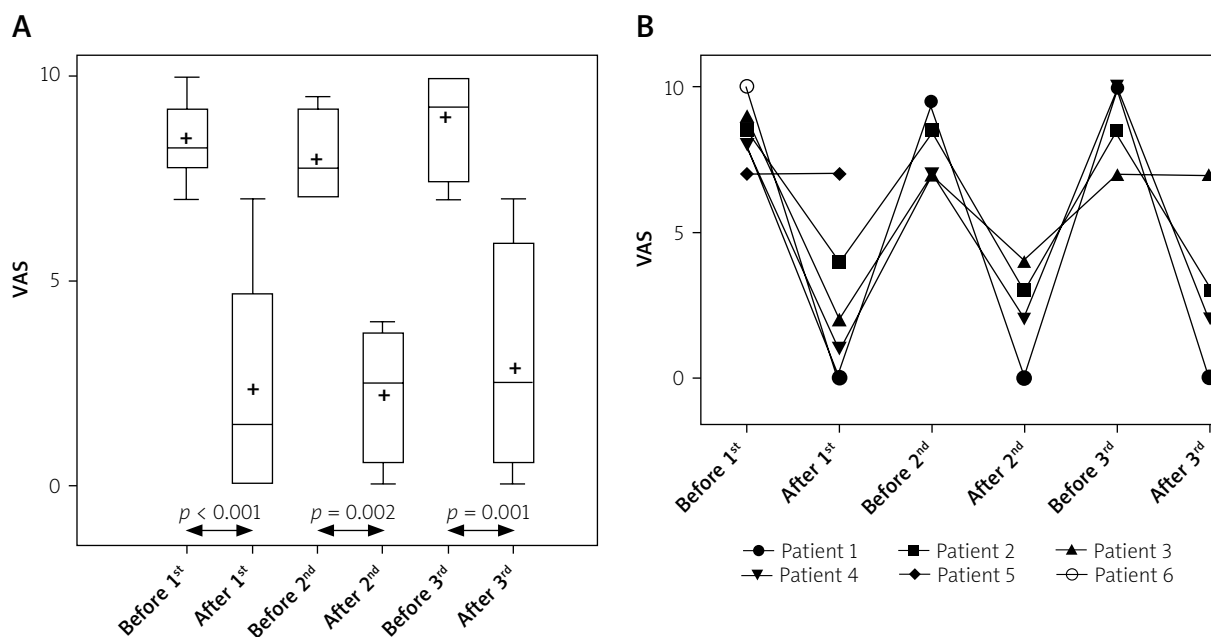
Pruritus caused by cholestasis is a challenging problem to manage, and conventional antipruritic treatments often lack efficacy. Both the European Association for the Study of the Liver (EASL) and the American Association for the Study of Liver Diseases (AASLD) recommend step therapy for pruritus associated with cholestasis [2, 3]. The first-line treatment is pharmacological (anion-exchange resins (cholestyramine), rifampicin, naltrexone, sertraline). For patients who are resistant to pharmacological therapy, more invasive approaches should be considered such as extracorporeal albumin dialysis, plasmapheresis, and bile duct drainage [2, 3]. Upon inefficacy of all the above-mentioned treatments, liver transplantation may become a solution [1–3].

The Molecular Adsorbents Recirculating System (MARS<sup>®</sup>) is an extracorporeal albumin dialysis treatment that aims to clear the blood of metabolic waste products normally metabolized by the liver. It can be used for the removal of bilirubin, bile acids, and other toxins, which accumulate in the blood of liver failure patients waiting for liver transplantation [5], or it can be a supportive treatment of cholestasis [6]. The MARS procedure has been described in detail elsewhere [7–9].

In September 2019 we retrospectively reviewed records of patients treated at the Aarhus University Hospital in Denmark for refractory pruritus to identify patients qualified for MARS treatment. Upon identification, medical records of the patients were reviewed for age, gender, disease history, and pharmacological treatment history. The intensity of pruritus was assessed by a visual analogue scale (VAS), before and after each treatment, ranging from 0 (no pruritus) to 10 (unbearable pruritus).

We identified 6 cases of patients treated with MARS for refractory pruritus. The mean age of the patients was 51 years (range: 42–77 years). All patients were female. Five of them suffered from primary biliary cholangitis and 1 had genetic cholestasis. Before albumin dialysis all patients ( $n = 6$ ) were treated according to step therapy without satisfactory effect, defined as a failure to respond to 3 separate therapeutic agents. Cholestyramine was taken by 5 (83%) patients because anion-exchange resins are the first line of treatment. Rifampicin was taken by all the patients. Four patients were taking phenobarbital. Opiate receptor antagonists were taken by 1 patient. Upon failure of pharmacological treatment, patients were offered albumin dialysis.

MARS therapy was well tolerated in all patients, and no side effects were observed. There were no significant haemodynamic changes or bleeding events during dialysis. All but 1 patient experienced improvement after the first MARS treatment. The duration of relief ranged from 1 month to 7 months after the first MARS treatment, from 2 weeks to 3 months after the second MARS treatment, and from no effect to 2 months after the third MARS treatment. Three patients



**Figure 1.** Intensity of pruritus assessed by visual analogue scale (VAS) before and after treatment with MARS. The results of the VAS analysis in all patients (A) and changes of VAS scores in specific patients (B)

underwent liver transplantation, and for these patients the MARS treatment extended the time to orthotopic liver transplantation (OLTx) on average by 12 months (14.5 months, 8.5 months, and 13 months, respectively). One patient could not undergo OLTx due to advanced age, and 2 patients did not need OLTx. One of them restarted pharmacotherapy after the first MARS treatment due to mild itching, which was enough to achieve clinical improvement in intensity of pruritus, and the second patient is free from pruritus after a third MARS treatment (which was applied in December 2019, and relief lasts until now – 20<sup>th</sup> February 2020). In this case, after repeated MARS treatment, the need of liver transplant for patient number 1 has been postponed for almost 2 years due to tolerated intensity of pruritus.

Albumin dialysis decreased VAS score. Analysis of variance (mixed-effect paired analysis) revealed significant results between groups ( $p < 0.001$ ). The first MARS treatment improved VAS with a mean difference of  $-6.1$  (95% CI (confidence interval)  $-9.1$  to  $-3.1$ ;  $p < 0.001$ ). The second MARS treatment improved VAS with a mean difference of  $-5.8$  (95% CI:  $-9.4$  to  $-2.1$ ;  $p = 0.002$ ). The third MARS treatment improved VAS with a mean difference of  $-5.9$  (95% CI:  $-9.5$  to  $-2.2$ ;  $p = 0.001$ ). The mean duration of acceptable relief in patients after the first MARS treatment was 3.92 months. The results of the VAS analysis and changes of VAS scores in specific patients are presented in Figure 1.

In the presented case series, we report our experience in the management of intractable pruritus with the Mo-

lecular Adsorbent Recirculating System, assessing its efficacy and safety. Therapy resulted in a significant reduction in the severity of pruritus, and clinical improvement of symptoms was confirmed by changes of VAS. Albumin dialysis in these cholestatic patients was a symptomatic approach because the underlying disorders were not reversed by the medical treatment. Although MARS treatment is an invasive procedure, according to recommendations it should be considered as a therapeutic option before referring a patient for liver transplantation.

The MARS procedure seems to be an effective option for patients with pruritus of cholestasis, who do not respond to other therapeutic methods. Repeated MARS can provide relief from pruritus from a few weeks to several months and thus can successfully be used as a supportive therapy until liver transplantation (bridge-to-transplant). Further well-designed prospective studies are warranted to confirm the effectiveness of MARS treatment in patients with cholestasis.

### Conflict of interest

The authors declare no conflict of interest.

### References

1. Jones EA, Bergasa NV. Why do cholestatic patients itch? *Gut* 1996; 38: 644-5.
2. European Association for the Study of the Liver. EASL Clinical Practice Guidelines: management of cholestatic liver diseases. *J Hepatol* 2009; 51: 237-67.

3. Lindor KD, Bowlus CL, Boyer J, et al. Primary biliary cholangitis: 2018 Practice Guidance from the American Association for the Study of Liver Diseases. *Hepatology* 2019; 69: 394-419.
4. Schaefer B, Schaefer F, Wittmer D, et al. Molecular Adsorbents Recirculating System dialysis in children with cholestatic pruritus. *Pediatr Nephrol* 2012; 27: 829-34.
5. Węgrzyn D, Kutwin-Chojnacka A, Peszyński P, Węgrzyn W. Albumin dialysis using the molecular adsorbent recycling system MARS. *Anestezjol Intens Ter* 2005; 1: 17-20.
6. Anand JS, Chodorowski Z, Hajduk A, Waldman W. Cholestasis induced by parabolan successfully treated with the molecular adsorbent recirculating system. *ASAIO J* 2006; 52: 117-8.
7. Pares A, Cisneros L, Salmeron JM, et al. Extracorporeal albumin dialysis: a procedure for prolonged relief of intractable pruritus in patients with primary biliary cirrhosis. *Am J Gastroenterol* 2004; 99: 1105-10.
8. Mullhaupt B, Kullak-Ublick GA, Ambühl PM, et al. Successful use of the Molecular Adsorbent Recirculating System (MARS) in a patient with primary biliary cirrhosis (PBC) and treatment refractory pruritus. *Hepatol Res* 2003; 25: 442-6.
9. Torrance GW, Feeny D, Furlong W. Visual analog scales: do they have a role in the measurement of preferences for health states? *Med Decis Making* 2001; 21: 329-34.

**Received:** 8.12.2020

**Accepted:** 13.02.2021